

The Evaluation of Ketorolac (Acular LS[®]) to Improve Patient Comfort During the Induction Phase of Cyclosporin-A (Restasis[®] Ophthalmic Emulsion) Therapy

BARRY A. SCHECHTER

ABSTRACT

Purpose: The aim of this study was to determine if the concomitant use of ketorolac 0.4% and cyclosporin-A improves patient comfort during the induction phase in treating chronic dry eye disease.

Methods: Patients (n = 52) with clinically diagnosed dry eye were randomized to receive either cyclosporin-A monotherapy twice-daily (BID) or a BID adjunctive regimen of ketorolac, followed by the instillation of cyclosporin-A 10 min later. Study visits were at baseline, week 2, and week 6. At each study visit, patients underwent an evaluation for corneal staining, Schirmer's scores, and tear break-up time tests. Patients were asked to rate ocular comfort on a 4-point scale and to complete the ocular surface disease index (OSDI[®]). Changes from baseline readings were recorded at week-2 and week-6 visits, and final patient success on treatment regimen was evaluated at week 6.

Results: After 6 weeks, the mean ocular comfort score of adjunctive patients improved 2.55 ± 0.95 points, versus 1.53 ± 0.91 points for monotherapy ($P = 0.309$). The adjunctive regimen provided significantly greater corneal staining reductions versus monotherapy, mean reduction in staining of 1.74 ± 0.9 , versus 1.27 ± 0.56 ($P = 0.044$).

Conclusions: Concurrent ketorolac 0.4% use with cyclosporin-A significantly reduced corneal staining and increased comfort in the induction phase.

INTRODUCTION

DRY EYE DISEASE IS A COMMON CONDITION that affects up to 20% of adults 45 years of age or older.¹ Although dry eye can affect patients of either gender and any age, the condition is most prevalent in women, especially in the peri- and postmenopausal age groups. A recent study reported that dry eye disease affects over 3.2 million American women (middle-aged and older), and that prevalence increases as women age.²

Dry eye disease, an inflammatory condition

that may be mediated by activated T-cell lymphocytes,³ affects the ocular surface and lacrimal gland.⁴ The damage caused by dry eye disease may be irreversible, and despite the availability of various tear substitutes, many patients with dry eye syndrome can experience corneal pathology with a subsequent reduction in vision.⁵

Cyclosporin-A (Restasis[®], Allergan; Irvine, CA) has been shown to significantly reduce the number of activated T-lymphocytes within the conjunctiva,⁶ thereby minimizing the inflammation causing dry eye. Topical cyclosporin-A 0.05%

Florida Eye Microsurgical Institute, Boynton Beach, FL.

This study was funded by an unrestricted educational grant from Allergan, Inc. (Irvine, CA).

ophthalmic emulsion (Restasis; Allergan) increases tear production and improves the quality of naturally produced tears.

Commercial cyclosporin-A is the first approved therapeutic agent for the treatment of chronic dry eye and the only treatment modality that addresses the underlying pathology. In a large, randomized trial, topical cyclosporin-A 0.05% was reported to produce significant improvement in the signs and symptoms of dry eye disease in patients with significant aqueous deficiency and keratoconjunctivitis sicca.⁷ Topical cyclosporin has also been shown to be safe for long-term use and to provide high levels of patient satisfaction.⁷⁻⁹ The most commonly reported side-effect with cyclosporin therapy is mild ocular burning and stinging upon instillation at the commencement of therapy.⁷ Modalities for reducing this initial discomfort during the induction phase of cyclosporin therapy may encourage continued use of this effective dry eye therapy, thereby reducing the risk for irreversible ocular damage secondary to chronic inflammation. To improve patient comfort, clinicians frequently prescribe topical corticosteroids. Because these medications may not be safe for extended use,¹⁰⁻¹³ other ocular anti-inflammatory agents, such as nonsteroidal anti-inflammatory drugs (NSAIDs), may provide a safer alternative for improving ocular tolerability during the induction phase of cyclosporin. One member of this class, ketorolac ophthalmic solution 0.4%, has been shown to reduce ocular pain associated with cataract and refractive surgery and has a favorable safety profile.^{14,15}

The aim of this study was to determine if the concomitant use of ketorolac 0.4% (Acular LS[®]; Allergan) improves patient comfort during the initiation of treatment with topical cyclosporin-A for the treatment of chronic dry eye disease.

METHODS

This study was a single-center, randomized, 6-week, open-label clinical trial. Patients (n = 52) with clinically diagnosed dry eye were randomized to receive either cyclosporin-A monotherapy twice-daily (BID) with artificial tears BID or a BID adjunctive regimen of ketorolac, followed by the instillation of cyclosporin-A 10 min later. Patients who were unlikely to respond to cyclosporin therapy (including patients with radiation-induced

dryness or limbal stem cell deficiency) and those with lagophthalmos or other eyelid deformities were excluded. Patients were also excluded if corneal thinning was present and/or perforation might occur, if their medical history contraindicated the use of cyclosporine or NSAIDs, or if patients were pregnant or nursing females.

Study visits were at baseline, week 2, and week 6. At each study visit, patients underwent an evaluation for corneal staining (Lissamine green and fluorescein), Schirmer's (with anesthesia) scores, and tear break-up time (TBUT) tests. Patients were also asked to rate ocular comfort, burning, stinging, or foreign body sensation on a 4-point scale (where 1 = mild discomfort and 4 = severe discomfort) and to complete the ocular surface disease index (OSDI[®]). The OSDI is assessed on a scale of 0-100, with higher scores representing greater disability. The index demonstrates sensitivity and specificity in distinguishing between normal subjects and patients with dry eye disease (normal, mild to moderate, and severe) and effect on vision-related function. Changes from baseline readings were recorded at week-2 and week-6 visits, and final patient success of the treatment regimen was evaluated at week 6.

The protocol was in compliance with Good Clinical Practices (GCP) and the Declaration of Helsinki (1996) and in accordance with applicable Institutional Review Board (IRB) regulations (United States 21 Code of Federal Regulations [U.S. 21 CFR] part 56.103). Study participants gave informed consent prior to the initiation of any study-related procedures. This study was performed in compliance with informed consent regulations (U.S. 21 CFR part 50) and was in accordance with HIPAA regulations.

Statistical analysis

Differences between treatment groups were analyzed with two-sample Student *t* tests, whereas within-group differences were evaluated with paired sample *t* tests. All tests were of a two-tailed null hypothesis of no difference between treatment regimens. The a priori alpha level for all tests was 0.05.

RESULTS

There were no significant between-group differences in any patient demographic variable

TABLE 1. PATIENT DEMOGRAPHICS

	Cyclosporine	Cyclosporine/ Ketorolac	Between-group P-value
N	27	25	
Mean age	68	66.3	0.754
Gender			0.418
Male	5	7	
Female	22	18	
Race			0.492
Caucasian	23	19	
African-American	2	1	
Hispanic	2	5	

Note: Patient characteristics in each treatment group at baseline. There were no significant between-group differences in any demographic variable.

T1 (Table 1). Both treatment regimens provided statistically significant improvements in ocular comfort at each follow-up study visit ($P < 0.001$), but the adjunctive regimen of ketorolac 0.4% and cyclosporin-A provided greater improvement in ocular comfort, as compared to cyclosporin monotherapy. This between-group difference was most pronounced at the week-2 follow-up visit, with a mean improvement of 1.67 ± 1.18 in the adjunctive group, compared with a mean improvement of 0.89 ± 0.83 in the monotherapy group ($P = 0.014$; Fig. 1). After 6 weeks of therapy, patients using adjunctive cyclosporin-A/ketorolac 0.4% continued to have greater improvements in mean ocular comfort scores, compared with patients using cyclosporin-A alone (mean improvement of 2.55 ± 0.95 with the adjunctive regimen, compared with 1.53 ± 0.91 points with monotherapy [$P = 0.309$]).

Both treatment regimens provided statistically significant reductions in corneal staining at each follow-up study visit ($P < 0.001$). The adjunctive regimen of cyclosporin/ketorolac, however, provided a greater mean reduction in corneal staining, compared with cyclosporine monotherapy. After 6 weeks, the mean reduction in corneal staining was 1.74 ± 0.9 with cyclosporin/ketorolac, compared with 1.27 ± 0.56 with cyclosporin monotherapy (Fig. 2).

At the 6 week follow-up visit, the mean improvement in OSDI scores was greater in the cyclosporin/ketorolac group than in the cyclosporin monotherapy group, with a mean reduction in OSDI score of 23.85 ± 21.42 points with cyclosporin/ketorolac and 15.03 ± 11.99 points with cyclosporin monotherapy (Fig. 3). This difference trended toward statistical significance ($P = 0.096$).

Other outcome measures

No corneal adverse events were observed during this 6-week trial. There were no significant between-group differences in mean change in Schirmer's scores or TBUT after 6 weeks of treatment ($P \geq 0.591$). Moreover, adjunctive use of ketorolac with cyclosporin during the initial induction phase of therapy reduced patient phone calls and office visits, compared with patients using cyclosporin monotherapy.

DISCUSSION

In this study, the addition of ketorolac to cyclosporin during the first few weeks of treatment provided significantly greater patient comfort during the initiation of cyclosporin therapy. The impact of adding ketorolac to cyclosporin was

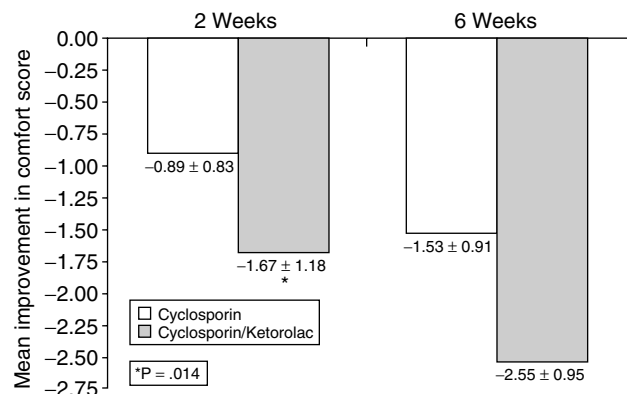


FIG. 1. Concomitant therapy with cyclosporin and ketorolac provided higher mean improvement in comfort at both study visits than that provided by cyclosporin alone. The difference was statistically significant at week 2 ($P = 0.014$).

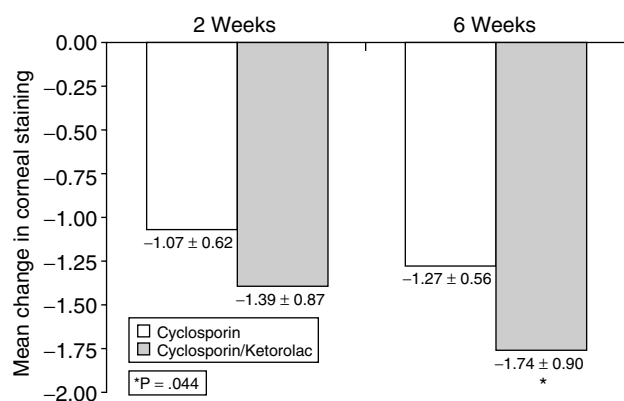


FIG. 2. Concomitant therapy with cyclosporin and ketorolac provided higher mean change in corneal staining at both study visits than that provided by cyclosporin alone. The difference was statistically significant at week 6 ($P = 0.044$).

most evident during the first 2 weeks, with patients receiving the adjunctive regimen reporting an improvement in comfort that was approximately twice that reported in the cyclosporin monotherapy group. Even after 6 weeks of therapy, patients using adjunctive cyclosporin/ketorolac continued to have greater improvements in mean ocular comfort scores, compared with patients using cyclosporin alone with artificial tears BID.

The greater mean improvements in ocular signs and symptoms in the adjunctive group, compared with the monotherapy group, are likely owing to the increase in patient comfort likewise provided by ketorolac. Most likely, increasing comfort likewise increased patient compliance with their prescribed cyclosporin regimen. It follows that patients who are more compliant with their cyclosporin regimen would be expected to have the greatest improvements in dry eye signs and symptoms.

The adjunctive use of ketorolac 0.4% with cyclosporin also reduced the number of patient phone calls and unscheduled office visits, compared with patients using cyclosporin alone. Increased patient comfort and satisfaction thereby freed office staff and the physician to use time more effectively.

In this study, ketorolac was safe, and no adverse events were reported. These findings suggest that ketorolac is an effective alternative to the use of topical corticosteroids for improving patient comfort and compliance during the induction of cyclosporin therapy. This is an important

finding, as topical corticosteroids are often prescribed during cyclosporin induction, despite the potential for serious side-effects, including elevated IOP, development of cataracts, and potential reactivation of viral keratitis.¹⁰⁻¹³ Conversely, many clinicians are hesitant to prescribe topical NSAIDs for long-term use because of prior reports of corneal melting associated with topical NSAIDs.^{16,17} However, analysis of NSAID-associated corneal events implicates the now-defunct generic diclofenac product, diclofenac sodium ophthalmic solution, as the agent primarily responsible.¹⁷ The demonstrated safety of ketorolac throughout the 6-week follow-up period in our study suggests that this drug is safe for extended use in patients who need to improve compliance during the initiation stage of cyclosporin therapy. In the author's experience, patients with more severe dry eye symptoms and associated severity of ocular surface damage are likely to experience enough improvement after the use of cyclosporin for 6 weeks that the concomitant use of ketorolac is no longer needed. However, the author has successfully used concomitant ketorolac and cyclosporin for as long as 12 months without any adverse effects. Use of ketorolac beyond this time frame, however, should be evaluated in longer-term, controlled studies to conclusively demonstrate the safety of this class of medications.

CONCLUSIONS

The adjunctive use of ketorolac 0.4% (Acular LS) with cyclosporin 0.05% ophthalmic emulsion

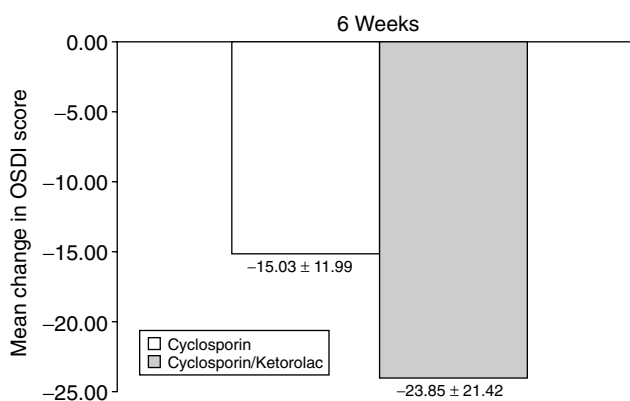


FIG. 3. Concomitant therapy with cyclosporin and ketorolac provided higher mean improvement in the OSDI at week 6 than that provided by cyclosporin alone. OSDI, ocular surface disease index.

(Restasis) improved patient comfort and may have increased patient compliance during the induction phase of cyclosporin therapy. Increased compliance with the prescribed cyclosporin regimen resulted in significant improvements in ocular inflammation and patient symptoms. Studies with a greater number of patients should be undertaken to further evaluate the results from this pilot study and patients with systemic or local conditions that may predispose them to corneal pathology should be closely monitored. However, these findings suggest that the analgesic properties of NSAIDs may prove to be a viable alternative to steroids during the induction phase of cyclosporin to increase patient compliance and comfort.

REFERENCES

1. Brewitt, H., and Sistani, F. Dry eye disease: The scale of the problem. *Surv. Ophthalmol.* 45(Suppl):199–202, 2001.
2. Schaumberg, D.A., Sullivan, D.A., Buring, J.E., et al. Prevalence of dry eye syndrome among U.S. women. *Am. J. Ophthalmol.* 136:318–326, 2003.
3. Perry, H.D., and Donnenfeld, E.D. Topical 0.05% cyclosporine in the treatment of dry eye. *Exp. Opin. Pharmacother.* 5:2099–2107, 2004.
4. Pflugfelder, S.C. Antiinflammatory therapy for dry eye. *Am. J. Ophthalmol.* 137:337–342, 2004.
5. Guerrissi, J.O., and Belmonte, J. Surgical treatment of dry eye syndrome: Conjunctival graft of the minor salivary gland. *J. Craniofac. Surg.* 15:6–10, 2004.
6. Kunert, K.S., Tisdale, A.S., Stern, M.E., et al. Analysis of topical cyclosporine treatment of patients with dry eye syndrome: Effect on conjunctival lymphocytes. *Arch. Ophthalmol.* 118:1489–1496, 2000.
7. Sall, K., Stevenson, O.D., Mundorf, T.K., et al. Two multicenter, randomized studies of the efficacy and safety of cyclosporine ophthalmic emulsion in moderate to severe dry eye disease. *Ophthalmology* 107:631–636, 2000.
8. Cross, W.D., Lay, L.F., Jr., Walt, J.G., et al. Clinical and economic implications of topical cyclosporine-A for the treatment of dry eye. *Manag. Care Interface* 15:44–49, 2002.
9. Small, D.S., Acheampong, A., Reis, B., et al. Blood concentrations of cyclosporine-A during long-term treatment with cyclosporine-A ophthalmic emulsions in patients with moderate to severe dry eye disease. *J. Ocul. Pharmacol. Ther.* 18:411–418, 2002.
10. Bertelmann, E., and Pleyer, U. Immunomodulatory therapy in ophthalmology—is there a place for topical application? *Ophthalmologica* 218:359–367, 2004.
11. Ishida, Y., Kato, T., Minamoto, A., et al. Retinal pigment epithelial tear in a patient with central serous chorioretinopathy treated with corticosteroids. *Retina* 24:633–636, 2004.
12. Yeung, C.K., Chan, K.P., Chan, C.K., et al. Cytotoxicity of triamcinolone on cultured human retinal pigment epithelial cells: Comparison with dexamethasone and hydrocortisone. *Jpn. J. Ophthalmol.* 48:236–242, 2004.
13. Garrott, H.M., and Walland, M.J. Glaucoma from topical corticosteroids to the eyelids. *Clin. Exp. Ophthalmol.* 32:224–226, 2004.
14. Price, M.O., and Price, F.W. Efficacy of topical ketorolac tromethamine 0.4% for control of pain or discomfort associated with cataract surgery. *Curr. Med. Res. Opin.* 20:2015–2019, 2004.
15. Solomon, K.D., Donnenfeld, E.D., Raizman, M., et al. Safety and efficacy of ketorolac tromethamine 0.4% ophthalmic solution in postphotorefractive keratectomy patients. *J. Cataract Refract. Surg.* 30:1653–1660, 2004.
16. Flach, A.J. Corneal melts associated with topically applied nonsteroidal anti-inflammatory drugs. *Trans. Am. Ophthalmol. Soc.* 2001. 99:205–210, discussion 210–212.
17. Gaynes, B.I., and Fiscella, R. Topical nonsteroidal anti-inflammatory drugs for ophthalmic use: A safety review. *Drug Saf.* 25:233–250, 2002.

Received: November 7, 2005

Accepted: January 4, 2006

Reprint Requests: Barry A Schechter
 Florida Eye Microsurgical Institute
 1717 Woolbright Road
 Boynton Beach, FL 33426

E-mail: BDSCH77@aol.com

BARRY A. SCHECHTER

AU1

Running title must be 45 char or less per AMA

AU2

Pls. spell out "HIPAA" in 3rd para under Methods

AU3

Should there be a box with a *P* value like Figs. 1 & 2?